



# International Journal of Fauna and Biological Studies

Available online at [www.faunajournal.com](http://www.faunajournal.com)

I  
J  
F  
B  
S  
International  
Journal of  
Fauna And  
Biological  
Studies

ISSN 2347-2677  
IJFBS 2015; 2 (3): 36-39  
Received: 17-02-2015  
Accepted: 10-03-2015

**Shazia Nisar**  
Department of Zoology, University  
of Karachi, Karachi-75270,  
Pakistan.

**M. Farhanullah Khan**  
Department of Zoology, University  
of Karachi, Karachi-75270,  
Pakistan.

**Aly Khan**  
Crop Diseases Research Institute,  
PARC, University of Karachi,  
Karachi-75270, Pakistan.

**M. Arshad Azmi**  
Department of Zoology, University  
of Karachi, Karachi-75270,  
Pakistan.

**Uzma Mehboob**  
Department of Zoology, Federal  
Urdu University of Arts, Science  
and Technology, Gulshan – e-  
Iqbal Campus, Karachi,  
75300, Pakistan.

**Abid Raza**  
Department of Environmental  
Science, Federal Urdu University  
of Arts, Science and Technology,  
Gulshan – e- Iqbal Campus,  
Karachi, 75300, Pakistan.

**Correspondence:**  
**Abid Raza**  
Department of Environmental  
Science, Federal Urdu University  
of Arts, Science and Technology,  
Gulshan – e- Iqbal Campus,  
Karachi, 75300, Pakistan.

## Histopathological changes of intestine of pigeon (*Columba livia*) artificially infected with *C. digonopora* and *C. cuneata*.

Shazia Nisar, M. Farhanullah Khan, Aly Khan, M. Arshad Azmi, Uzma  
Mehboob, Abid Raza

### Abstract

The aim of study was to observe histopathological changes in intestines of *Columba livia* artificially infected with *C. digonopora* and *C. cuneata*. In *C. digonopora* infested pigeon infiltration of inflammatory cells in lamina propria were noticed and some portion of worm were seen in muscular layer. Serosa was necrotic. In *C. cuneata* infested pigeon migratory tunnels formed along with fibrosis, necrosis and villous atrophy.

**Keywords:** Histopathological changes, *C. digonopora* & *C. cuneata* infection, *Columba livia*

### 1. Introduction

Cestode infection is very common in birds. 23.5% of birds were infected with Cestodes [1]. Most pigeons were infected with cestodes & 75% of cestodes were *Raillietina spp.* [2, 3]. These parasites cause severe histological changes in the host. The cestodes inflict gross lesions including congestion, inflammation, nodules formation in intestinal mucosa and pin point hemorrhages [4]. Different species of cestodes cause severe destruction of villi, desquamation & degeneration of epithelial cells [5]. Abundant work has been done on histopathology of different birds [6]. Observed histopathological changes in heart & gizzard of quail chicks *Coturnixcoturnix japonica* [7]. Observed histopathological changes in pigeon suffering from new castle diseases [8]. Observed histological changes in intestine of female lesser flamingo infected with multiple cestodes, cestodes dilated the absorbing power of intestine for nutrients & vitamins [9]. Histopathology has great importance in the diagnosis of disease. Aim of study was to observe histological changes in pigeon caused by *C. digonopora* and *C. cuneata* infection.

### 2. Materials and Methods

Animal breeder of Department of Zoology Parasitology section University of Karachi provided artificially infected animals. Animals were sacrificed and infected guts were collected for histopathological studies. A small piece of tissue was put into 10% formalin. Bouin's fluid was used as second fixative. Dehydration was done in an ascending series. Tissues were cleared with cedar wood oil and three times of xylene for 30-60 min. At the temperature of 60-65 °C tissues were immersed in melted paraffin and xylene (1-1) and then three baths in pure melting paraffin. Tissue was poured into block cavity having slightly solidified wax, then tissue was covered with melted paraffin wax. Microtomy was done by putting 6.4 m thick strip on slide, warmed it and placed in oven at 40 °C for 6 hours. Double staining method was used. Slides were washed two times with xylene, descending alcohol series and then water.

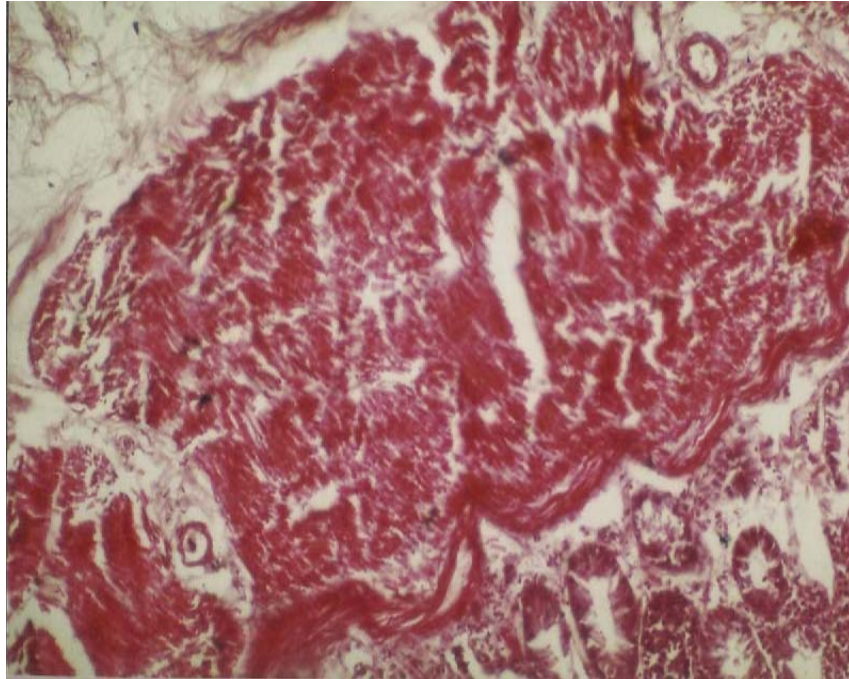
Slides were stain in haematoxylin for 1 to 3 min. After washing in ascending alcohol series, Slides were dyed with eosin for 10-30 sec. and those 8 to 10 dips in 100% alcohol. After double wash of xylene, slides mounted with Canada balsam.

### 3. Results

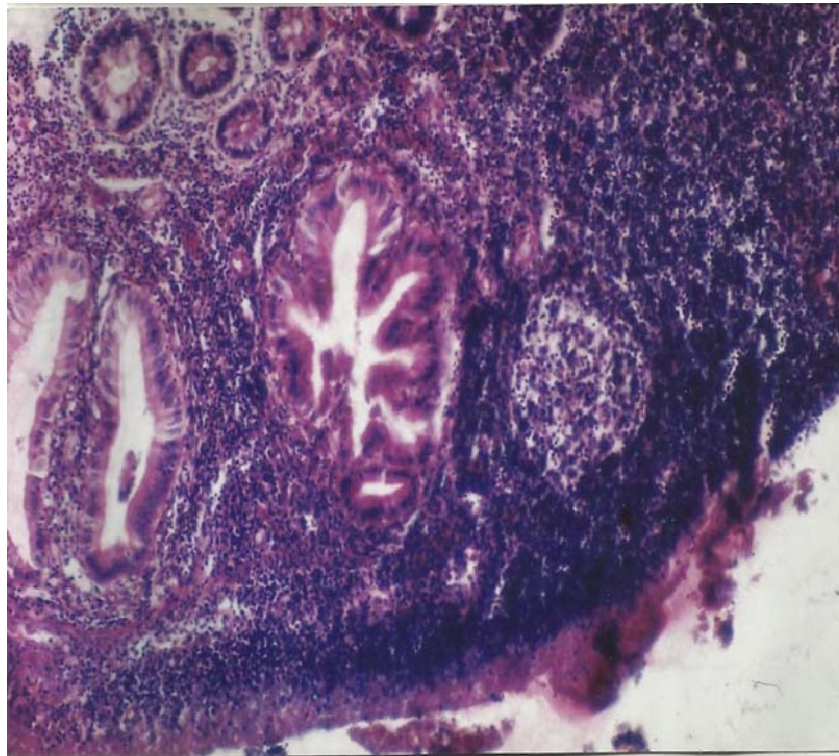Intestines of *Columba livia* were artificially infected with *C. digonopora* (Fig 1 & 2) and *C. cuneata* (Fig 3 & Fig 4) caused severe damages. Parasites were infiltrated the muscular

layer. Sometime portion of parasites remained in muscular layer. Histopathology revealed some portion of cestodes embedded in muscularis externa (Fig 1 and Fig 2). Atrophy of muscularis externa was seen. Due to shrinkage of muscularis fibers, empty spaces and migratory tunnel were produced (Fig 1). Serosa was necrotic. Due to infection, lamina propia was heavily infiltrated by inflammatory cells (Fig 1 and Fig 2).

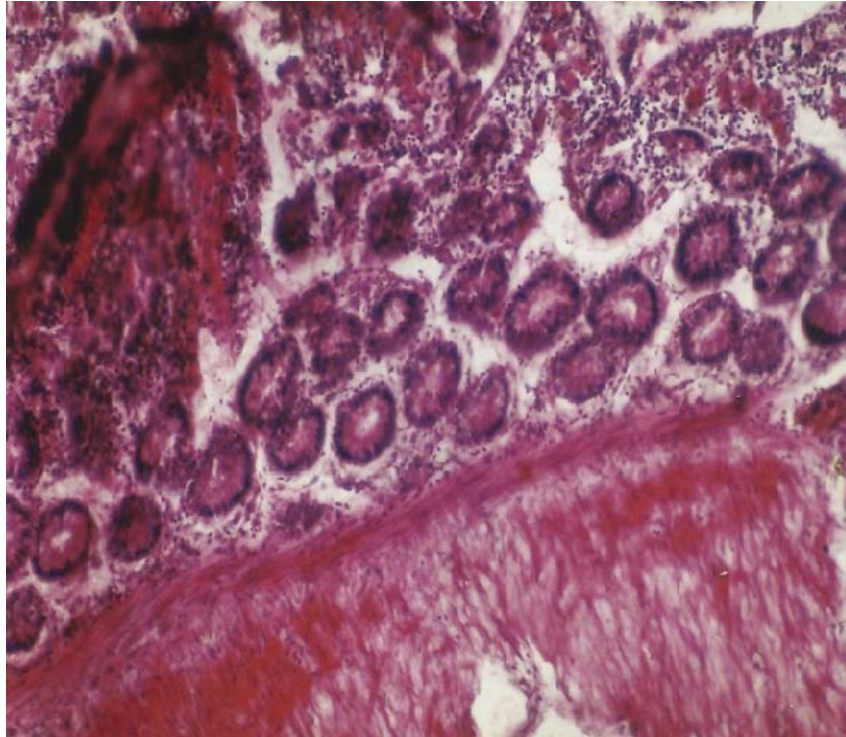
Parasites created migratory tunnels during infection, fibrosis was observed. Necrosis of gland cells was obvious (Fig 3). Mucosal necrosis and villous atrophy along with degeneration and dislocation of villi and gland cells were observed. Morphology and orientation of intestinal villi were changed due to infection. Some gland cells seem to be clustered due to formation of migratory track (Fig 4).



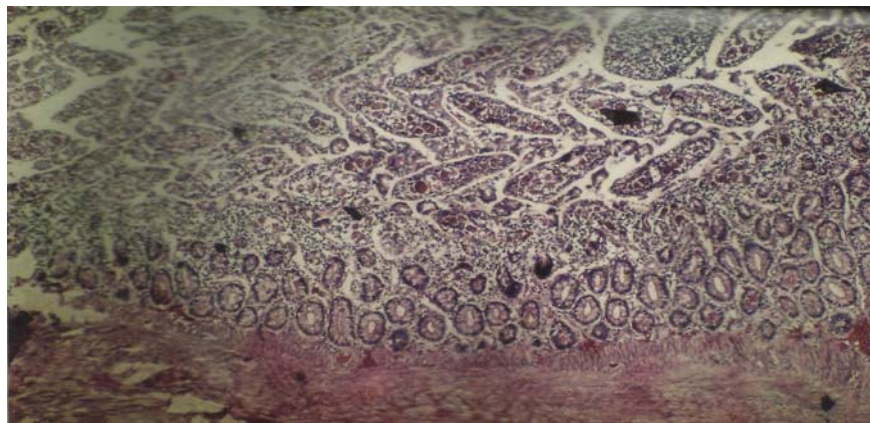
**Fig 1:** Histological section of small intestine of *Columba livia* infected with *C. digonopora* showing parasite portion with serosal necrosis. X100



**Fig 2:** Histological section of small intestine of *C. livia* infected with *C. digonopora* showing portion of parasite and infiltration of inflammatory cells. X100



**Fig 3:** Photomicrograph of small intestine of *Columba livia* infected with *C. cuneata* showing fibrosis and necrosis of gland cells. X50



**Fig 4:** Photomicrograph of small intestine of *C. livia* infected with *C. cuneata* showing degeneration of villi. X25

#### 4. Discussion

Morphology and orientation of intestinal tissue were changed due to infection of parasites. Many workers worked on histopathology of intestine infected with cestode. Following observations were noticed in parasitic infected intestine of Pigeon. Some parasitic portion remained in muscular layer. Cestodes made migratory tunnel during migration. Lamina propria was infiltrated by inflammatory cells due to infection. Orientation of villi was changed. Villi and gland cells were degenerated and dislocated. Serosal and mucosal necrosis and fibrosis was observed. Many workers agreed with these results [8]. Worked on cestodiasis in a lesser flamingo, observed cestodes scolices were embedded at the base of crypts between villi and also agree with fibrosis in muscular layer and infiltration of lymphocyte [10]. Worked on lesions created by gastrointestinal parasites in Guinea fowls agreed with attachment of parasites in intestine. Attachment of nematode and cestodes were noticed with mucosa of Ilium and also observed convoluted tracks in crop mucosa, necrosis of gland

Cells, infiltration of inflammatory cells in lamina propria in intestine of infected Guinea fowl [11]. Observed villous atrophy in *R.echinobothrida* infection in domestic fowl [12]. Reported degeneration of sub mucosal glands and epithelium along with cellular infiltration in indigenous and exotic layers of gut of poultry [5]. Worked on helminthiasis pathology in desi fowls, reported same results along with thickening of sub mucosa and mucosa of intestine infected with *R. cesticillus* in desi fowl [13]. Observe infiltration of inflammatory cells in lamina propria.

#### 5. References

1. Dranzoa C, Ocaido M, Ketele P. The ecto-gastro-intestinal and heamo-parasites of live pigeons (*Columba livia*) in Kampala, Uganda. *Avian Pathology* 1999; 28:119-124.
2. Kumaran V, Kunjan PN, Nadakal MA. New species from pigeon. *JPN J parasitol* 1981; 30(3)241-244.
3. Mushi EZ, Binta MG, Chab RG, debele NR, R Panzirah. Helminth Parasites of domestic Pigeons (*Columba livia domestica*) in sebele, Gaborane, Botswana. *Onderstepoort*

- J vet Res 2000; 67(1):75-76.
4. Bhowmik MK, Sinha PK. Studies on the pathology of taeniasis in domestic fowl. Ind Vet J 1983; 60:6-8.
  5. Padhi BC, Misra SC, Panda DN. Pathology of helminthiasis in Desi fowls. Icastode infection. Ind J Anim Hlth 1986; 25:127-131.
  6. Riaz S, Alam SS, Ikram A. Histopathological changes observed in the heart and gizzard of quail chicks *Coturnixcoturnix japonica* administrated by the different levels of chrome shaving. African Journal of Biotechnology 2006; 5(19):1765-1769.
  7. Shaheen S, Anjum AD, Rizvi F. Clinico-pathological observation of pigeons (*Columba livia*) suffering from new castle disease. Pakistan Vet J 2005; 25(1):5-8.
  8. Sarah L, Poynton, Mukherjee G, John D. Cestodiasis with intestinal diverticulosis in a lesser flamingo (*Phoeniconaias minor*). Journal of zoo and wild life medicine 2000; 31(1):96-99.
  9. Hayat B, Hayat CS. Incidence of intestinal parasites of chicken in Faislabad district. Pak vet J 1983; 3:165-167.
  10. Bawe NM, Joseph AO, Idris AR, Esievo KAN. Observation of lesion associated with gastrointestinal parasites of guinea fowls (*Numida meleagris galeata*) in Zaria Nigeria. ISAH 2005; 2:511-513.
  11. Samad MA, Alam MM, Bari ASM. Effect of *R. echinobothrida* infection on blood values and intestinal tissues of domestic fowls of Bangladesh. Vet. Parasitol 1986; 21:279-284.
  12. Anwer AH, Rana SH, Shah AH, Khan MN, Akhter MZ. Pathology of cestodes infection in indigenous and exotic layers Pah J sci 2000; 37(1-2):93-94.
  13. Rodriguez F, Ores J, Rodriguez L, Gonzalez j, Castro P, Fernandez A. Intestinal cryptosporidiosis in pigeon (*Columba livia*). Avain diseases 1996; 41:748-756.